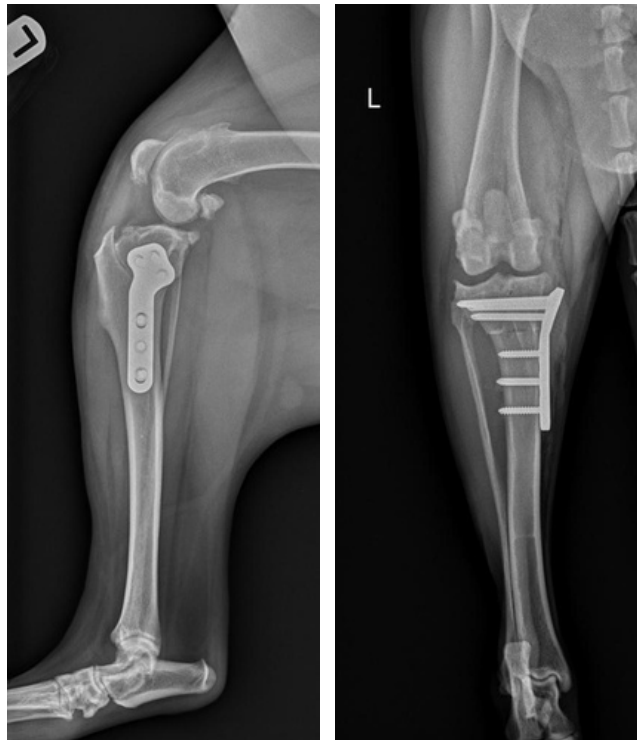


POSITIONING FOR TPLO RADIOGRAPHS

LATERAL 90:90 VIEW:

- The tibia should be parallel to the table top with the crosshairs centered over the stifle
- The stifle and hock should both be flexed 90 degrees (hence 90:90 film)
- The opposite leg should be pulled out of the way
- The femoral condyle should overlap
- The entire stifle and hock should be in view



CRANIOCAUDAL OR CAUDOCRANIAL:

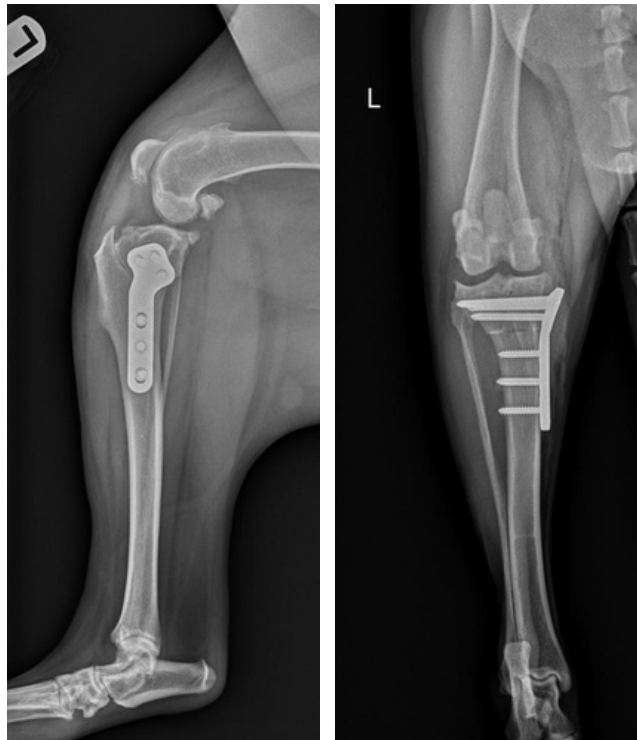
- The tibia should be parallel to the table top with the crosshairs centered over the stifle
- Fully extend the limb
- The patella should be centered on the femoral condyle
- The fabellae should bisect the femoral cortex
- The entire stifle and hock should be in view



POSITIONING FOR TPLO RADIOGRAPHS

LATERAL 90:90 VIEW:

- The tibia should be parallel to the table top with the crosshairs centered over the stifle
- The stifle and hock should both be flexed 90 degrees (hence 90:90 film)
- The opposite leg should be pulled out of the way
- The femoral condyle should overlap
- The entire stifle and hock should be in view



CRANIOCAUDAL OR CAUDOCRANIAL:

- The tibia should be parallel to the table top with the crosshairs centered over the stifle
- Fully extended the limb
- The patella should be centered on the femoral condyle
- The fabellae should bisect the femoral cortex
- The entire stifle and hock should be in view

